

# Extensive Maxillary Necrosis Following Tooth Extraction

Pavan M. Patil, MDS, DNB,\* and Punam Bhadani, MD†

## Case Presentation

A previously healthy 52-year-old woman presented with painful unhealed extraction sockets in the maxillary right posterior region. No evidence of previous local or total body irradiation, transplantation, iatrogenic immunosuppression, blood transfusion, tuberculosis, or acquired immunodeficiency syndrome was found in the patient's medical history. She had undergone extraction of her right maxillary premolars and molars at a local dental clinic 1 week before presentation owing to pain and mobility with those teeth. There was no history of noticeable swelling, ulceration, or mucosal changes in relation to the maxillary right posterior teeth or the palate at the time of extractions. She denied any medical ailments and allergies and was not on any medications. She was in extreme pain, which was aggravated upon bending forward, and denied any oral or nasal discharge, dysphagia, neurosensory disturbance, foul odor, persistent cough, night sweats, headache, or recent weight loss. She complained of partial right nasal obstruction. She had an increased body temperature of 100.7°F and appeared cachectic. Blood pressure was 160/90 mm Hg. Pulse rate was 90 beats/min, and respiratory rate was 16 breaths/min. She denied alcohol or tobacco use. Oral examination showed a large necrotic area in the right maxilla extending distally from the right maxillary canine to posteriorly beyond the right maxillary tuberosity, medially to the midline of the palate, and buccally to the depth of the maxillary vestibule (Fig 1). Examination of the adjacent intraoral mucosa and pharynx was unremarkable. The right maxillary sinus was tender to palpation. Examination of the right nasal cavity revealed mucositis and a slight amount of pus but no mass lesion. Right eye movements, visual acuity, and pupillary reaction to light were normal. The neck was without lymphadenopathy. Fasting blood sugar was 90 mg/dL (normal, 60 to 90 mg/dL), and postprandial blood sugar level was 136 mg/dL (normal, 90 to 140 mg/dL). Urine was negative for ketone bodies and glucose. Blood chemistry revealed an increased white blood cell count ( $14.1 \times 10^3$ ) and a normal platelet count ( $395 \times 10^3$ ). The remain-

ing blood values were within normal levels. Serum urea was 38 mg/dL and serum creatinine was 0.9 mg/dL. Serum albumin and globulin levels were within normal range. Serum electrolytes were within normal range as were arterial blood gas levels. Enzyme-linked immunosorbent assay and Venereal Diseases Research Laboratory test results were reported as negative. A purified protein derivative test was reported to be negative. Computed tomographic (CT) scan of the maxilla and paranasal sinuses showed extensive alveolar destruction (Fig 2), mucosal thickening in the right maxillary antrum with destruction of the medial and posterolateral walls of the right maxillary sinus, and contiguous extension into the right nasal cavity (Fig 3). Involvement of the right ethmoidal and sphenoidal sinuses was also seen (Fig 4). No cranial or orbital involvement was seen on CT scan. Chest radiography was unremarkable.

## DIFFERENTIAL DIAGNOSIS

Clinical and CT features in this case led to a suspicion of an invasive infection or malignancy. Considering the age of the patient, a fungal opportunistic infection or malignancy of the maxillary sinus was likely. Other causes of maxillary necrosis needed to be considered, such as malignant salivary gland tumors, chronic granulomatous diseases, metastatic jaw tumors, local ischemic necrosis, and osteomyelitis of specific infections.

Mucormycosis of the maxillary sinus initially presents as intraoral swelling of the maxillary alveolar process and/or palate. Left untreated, this condition evolves into palatal ulceration, which appears black and necrotic. Extensive tissue destruction eventually follows if the condition remains untreated. Insulin-dependent diabetics who have uncontrolled diabetes and are ketoacidotic are especially prone to develop mucormycosis. Only rarely has this been reported in apparently healthy individuals.<sup>1,2</sup>

Aspergillosis of the oral cavity or paranasal sinus is rare in immunocompetent individuals. The usual appearance in a normal host is that of allergic fungal sinusitis or a low-grade infection in the maxillary sinus resulting in a mass of fungal hyphae called an *aspergilloma*. Invasive or disseminated forms typically occur in the immunocompromised host. Tooth extraction or endodontic treatment, especially in the maxillary posterior segments, leads to painful gingival ulceration, with the mucosa and soft tissues developing a gray or violaceous hue. In untreated cases extensive necrosis results and is seen clinically as a yellow or black ulcer and facial swelling evolves.<sup>2-6</sup>

Squamous cell carcinoma of the maxillary sinus presents as chronic ulcers with raised margins causing exposure of underlying bone. Other features seen in cases of antral carcinoma are local pain, swelling, epistaxis, nasal discharge, epiphora, diplopia, or numbness.<sup>7</sup>

Adenoid cystic carcinoma most commonly involves the palatal minor salivary glands, representing 8% to 15% of all palatal salivary neoplasms. It occurs most commonly in middle-aged adults and presents with early onset of pain even before there is noticeable swelling. Tumors arising

Received from Sharda University, Greater Noida, Uttar Pradesh, India.

\*Reader, Department of Oral and Maxillofacial Surgery, School of Dental Sciences.

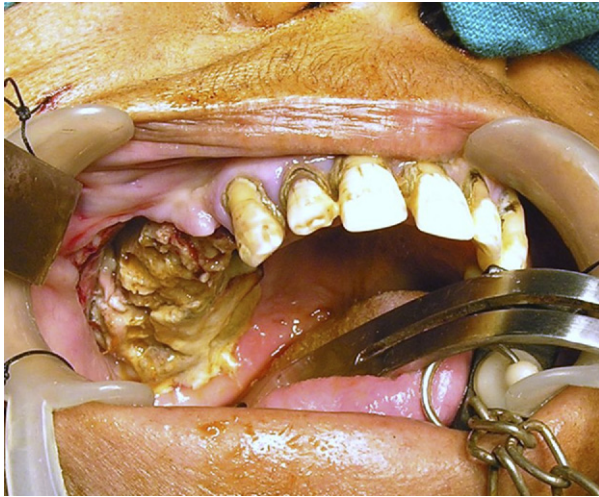†Professor, Department of Pathology, School of Medical Sciences and Research.

Address correspondence and reprint requests to Dr Patil: Department of Oral and Maxillofacial Surgery, School of Dental Sciences, Sharda University, Plot 32, 34, Knowledge Park 3, Greater Noida, Uttar Pradesh 201308, India; e-mail: [pavanpatil2000@yahoo.co.uk](mailto:pavanpatil2000@yahoo.co.uk)

© 2011 American Association of Oral and Maxillofacial Surgeons

0278-2391/11/6909-0022\$36.00/0

doi:10.1016/j.joms.2010.11.018

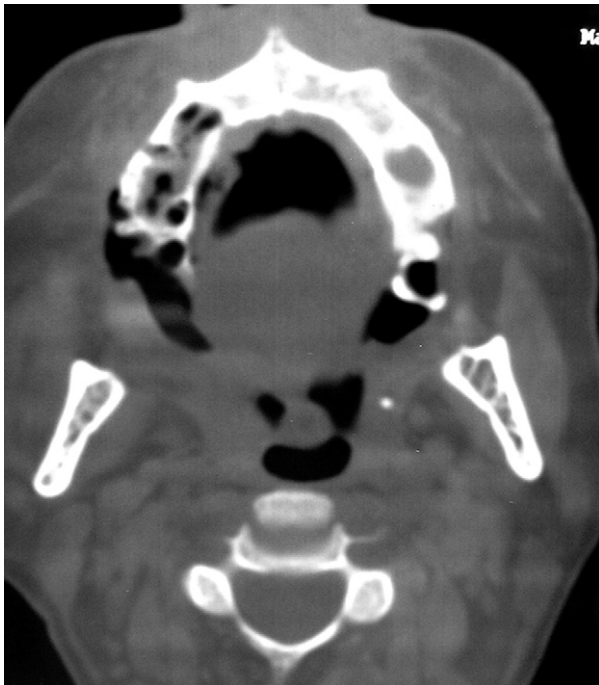


**FIGURE 1.** Maxillary necrosis.

*Patil and Bhadani. Extensive Maxillary Necrosis After Tooth Extraction. J Oral Maxillofac Surg 2011.*

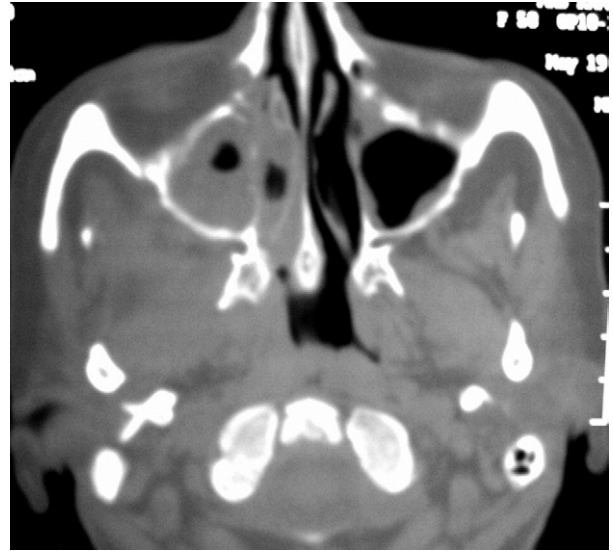
in the palate or maxillary sinus often show radiographic evidence of bone destruction. Metastasis to regional lymph nodes is uncommon.<sup>8</sup>

Carcinoma ex pleomorphic adenoma represents a malignant transformation of a previous pleomorphic adenoma, with peak prevalence in the sixth to eighth decades of life. Two thirds of minor salivary gland cases occur on the palate. Patients report a longstanding painless mass that has undergone a recent rapid growth associated with pain and an exophytic ulcerated mass.<sup>9</sup>



**FIGURE 2.** Axial computed tomogram showing extensive alveolar destruction.

*Patil and Bhadani. Extensive Maxillary Necrosis After Tooth Extraction. J Oral Maxillofac Surg 2011.*

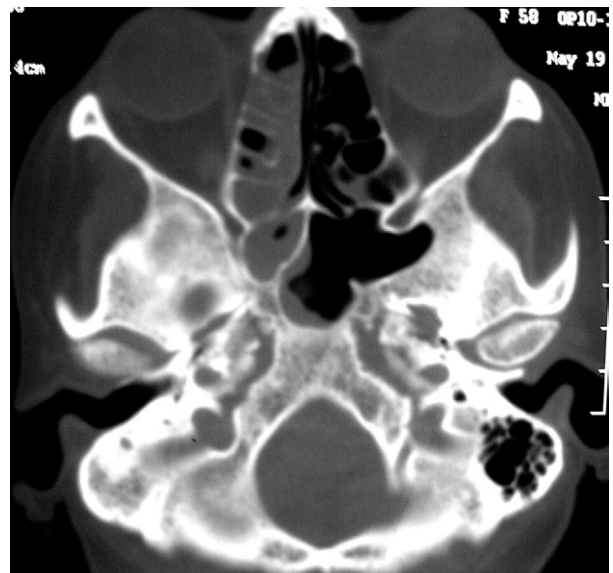

**FIGURE 3.** Axial computed tomogram showing right maxillary sinus and lateral nasal wall mucosal enlargement with erosion of the medial and posterolateral walls of the maxillary sinus.

*Patil and Bhadani. Extensive Maxillary Necrosis After Tooth Extraction. J Oral Maxillofac Surg 2011.*

Extranodal natural killer T-cell lymphoma (nasal-type angiocentric lymphoma or midline lethal granuloma) characteristically occurs in the midline, affecting the oronasal region. In the initial stages patients may report nasal stuffiness, pain, and palatal swelling. In later stages patients develop progressive areas of ulceration that can lead to bone necrosis and perforation.<sup>10</sup>

Wegener's granulomatosis is an uncommon condition characterized by a necrotizing granulomatous condition of the respiratory tract, widespread vasculitis, and necrotizing



**FIGURE 4.** Axial computed tomogram showing mucosal thickening of the right ethmoid air cells and sphenoid sinus.

*Patil and Bhadani. Extensive Maxillary Necrosis After Tooth Extraction. J Oral Maxillofac Surg 2011.*

glomerulonephritis. Common presenting signs and symptoms include sinusitis, rhinorrhea, nasal stuffiness and epistaxis with or without complaint of fever, arthralgia, and weight loss. Gingiva has a peculiar erythematous hyperplasia and is termed *strawberry gingivitis*. There may be destruction of underlying palatal and alveolar bone causing oroantral fistula.<sup>11</sup>

Necrotizing sialometaplasia is an uncommon, locally destructive inflammatory condition most commonly involving the palatal minor salivary glands and mimics a malignant process clinically and microscopically. It has been known to occur after palatal injections. It presents as nonulcerated swelling associated with pain or paresthesia followed by a craterlike ulcer after 2 to 3 weeks, with destruction of the underlying palatal bone occurring only rarely.<sup>12</sup>

Metastatic tumor to the maxilla presents with pain, swelling, loosening of teeth, a mass, or paresthesia. Not uncommonly, an osseous metastasis is discovered in a nonhealing extraction site in which the tooth was recently removed because of complaints of local pain or significant mobility. The oral tumor may be the first indication of the presence of a primary tumor in the lungs, kidney, prostate, breast, or thyroid gland.<sup>13</sup>

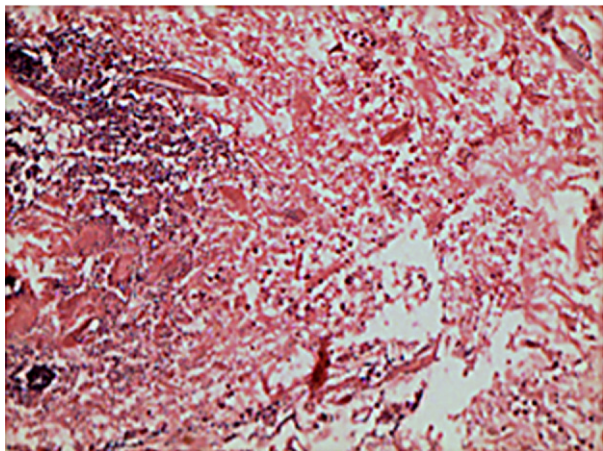
Bisphosphonate-associated osteonecrosis of the jaw can occur in patients on bisphosphonate therapy. In 60% of these cases, necrosis follows an invasive dental procedure, with the remainder occurring spontaneously.<sup>14</sup>

Osteoradionecrosis of the maxilla is a complication that can occur in patients who have undergone radiation therapy to the head and neck, frequently after local trauma such as tooth extraction and in some instances spontaneously.<sup>15</sup>

Tertiary syphilis presents with an active site of granulomatous inflammation known as a *gumma*, an indurated, nodular, or ulcerated lesion that may produce extensive tissue destruction. Intraoral lesions usually affect the palate or tongue, with palatal lesions frequently perforating through to the nasal cavity.<sup>16</sup>

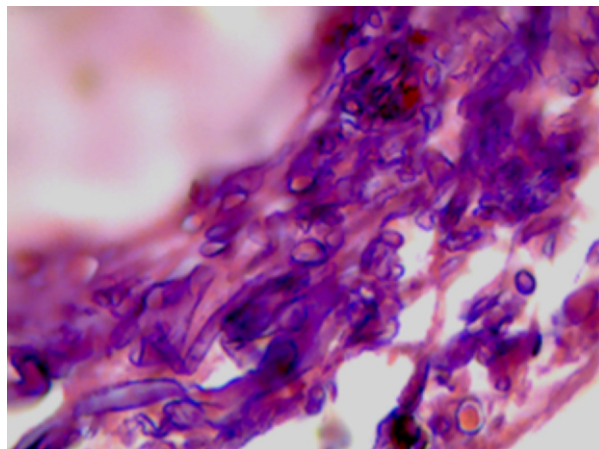
Tuberculous osteomyelitis of the jaws involves the gingiva, mucobuccal fold, and areas of inflammation adjacent to teeth or extraction sites in primary oral lesions or the palate, lip, and tongue in secondary oral lesions.<sup>17</sup>

Actinomycotic osteomyelitis of the maxilla can occur after trauma, periodontal infections, with nonvital teeth, or at ex-



**FIGURE 5.** Necrotic areas with septate fungal hyphae against a background of acute and chronic inflammatory cells and occasional giant cells (hematoxylin and eosin; magnification,  $\times 100$ ).

Patil and Bhadani. Extensive Maxillary Necrosis After Tooth Extraction. *J Oral Maxillofac Surg* 2011.



**FIGURE 6.** Septate acute angled branching hyphae typical of *Aspergillus* (periodic acid-Schiff; magnification,  $\times 100$ ).

Patil and Bhadani. Extensive Maxillary Necrosis After Tooth Extraction. *J Oral Maxillofac Surg* 2011.

traction sites and presents as ill-defined areas of radiolucency, often surrounded by radiopacity, with or without overlying soft tissue involvement.<sup>18,19</sup>

Herpes zoster involving the fifth cranial leading to necrosis of the alveolar process and adjacent bone of the right maxilla has been reported.<sup>20</sup> Contributing factors in the previously reported case were malignancy, corticosteroid therapy, and prior irradiation of the maxilla. Although these factors contributed to a decreased host resistance, evidence suggested that herpes zoster virus was the cause of the bone necrosis.

## DIAGNOSIS

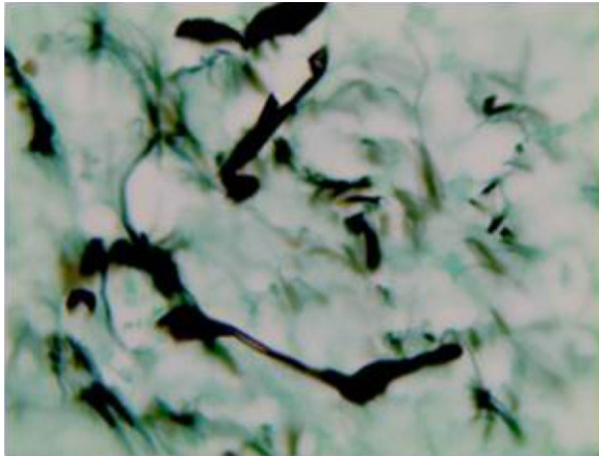
Based on the patient's history and CT findings, a clinical diagnosis of fungal paranasal sinusitis was made. Serum galactomannan antigen test result was reported to be positive on 2 consecutive occasions. This prompted the diagnosis of an *Aspergillus* infection. A biopsy was performed under local anesthesia and the specimen was submitted for microscopic interpretation. Histopathologic examination with hematoxylin and eosin (Fig 5) and periodic acid-Schiff (Fig 6) readily identified septate *Aspergillus* hyphae in a mass of necrotic tissue with acute and chronic inflammatory cells and occasional giant cells. A modified Grocott silver methenamine special staining technique further identified these septate acute angled branching hyphae of *Aspergillus* (Fig 7). The tissue culture grew *Aspergillus fumigatus* in Sabouraud agar media.

## FINAL DIAGNOSIS

The final diagnosis was invasive aspergillosis of the maxilla and paranasal sinuses.

## SUBSEQUENT COURSE

The patient gave written informed consent and institutional ethical committee approval was obtained. The patient was hospitalized and started on amphotericin B 0.8 mg/kg/day intravenously. Under left nasotracheal intubation, a partial maxillectomy and excision of the entire right maxillary sinus lining and the right lateral wall of the nose were performed under general anesthesia (Fig 8), leaving behind an intact right orbital floor. Sphenoidectomy and ethmoidectomy were performed. The patient was adminis-



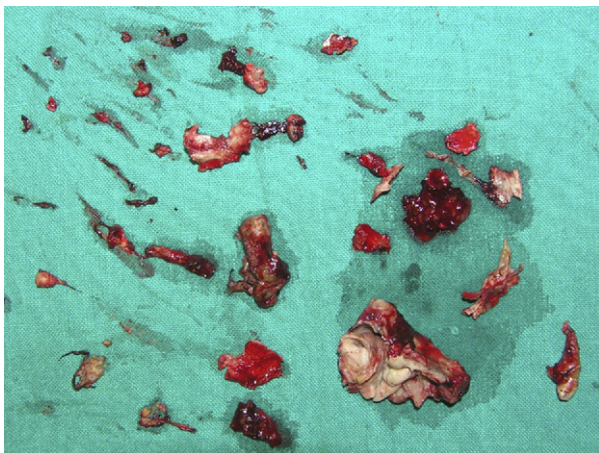
**FIGURE 7.** Aseptate acute angled branching of *Aspergillus* (Grocott silver methenamine; magnification,  $\times 100$ ).

Patil and Bhadani. *Extensive Maxillary Necrosis After Tooth Extraction. J Oral Maxillofac Surg* 2011.

tered amphotericin B 0.8 mg/kg/day intravenously for 6 weeks and the wound was dressed with a povidone iodine-soaked dressing and irrigated with povidone iodine solution daily. Amphotericin B was slowly infused over 4 to 6 hours, and blood urea and creatinine levels were monitored because the drug can cause renal toxicity. The area healed completely in 6 weeks (Fig 9). Serum galactomannan antigen test result was reported to be negative and antifungal therapy was terminated. An obturator was then constructed for the patient.

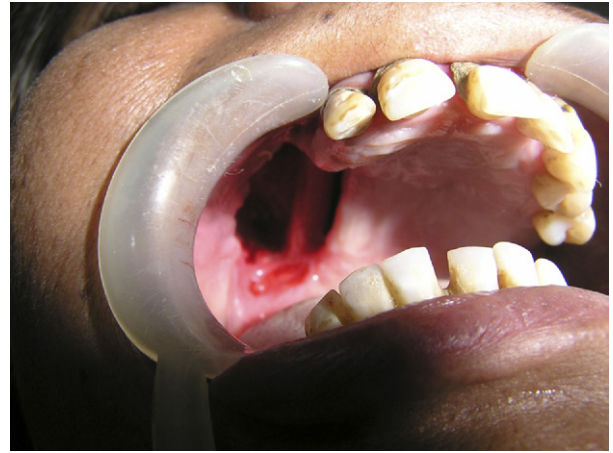## Discussion

The maxilla rarely undergoes necrosis because of rich vascularity. Maxillary necrosis can occur from bacterial infections such as osteomyelitis, viral infections such as herpes zoster, or fungal infections such as mucormycosis, aspergillosis, etc.<sup>6</sup> Opportunistic



**FIGURE 8.** Excised necrotic tissue.

Patil and Bhadani. *Extensive Maxillary Necrosis After Tooth Extraction. J Oral Maxillofac Surg* 2011.



**FIGURE 9.** Healed maxillary defect.

Patil and Bhadani. *Extensive Maxillary Necrosis After Tooth Extraction. J Oral Maxillofac Surg* 2011.

fungal infections such as aspergillosis usually occur in immunocompromised patients but also can infect healthy individuals.<sup>2,6</sup> These infections are opportunistic—they occur when organisms to which humans are frequently exposed gain entry to the body owing to a decrease in host defenses or through an invasive portal such as a dental extraction. The fungus invades the arteries, leading to thrombosis that subsequently causes necrosis of hard and soft tissues.<sup>21</sup> The infection can spread to orbital and intracranial structures by direct invasion or through the blood vessels.<sup>22</sup> Predisposing factors for aspergillosis are uncontrolled diabetes (particularly in patients with ketoacidosis), malignancies such as lymphomas and leukemias, renal failure, organ transplantation, long-term corticosteroid and immunosuppressive therapies, cirrhosis, burns, protein-energy malnutrition, and acquired immunodeficiency syndrome.<sup>4,21,23</sup> Certain conditions may change the normal ecosystem to allow fungal proliferation. The most common of these favorable conditions are prolonged antibiotic and corticosteroid treatments, nasal obstructions that aid blockage of the ostium and anaerobic conditions,<sup>24</sup> and endosinal penetrations at the time of a dental procedure such as root canal perforation, a canal overfilling,<sup>25,26</sup> or a dental extraction. Antral aspergillosis after tooth extraction or endodontics results in symptoms of localized pain, tenderness, and nasal discharge.<sup>25</sup> Untreated infection may lead to necrosis and palatal perforation. Clinical manifestations of aspergillosis vary depending on the immune status of the host and the presence or absence of tissue damage. In the normal host, the disease often presents as an allergy or a low-grade sinus infection resulting in the formation of a fungal mass or aspergilloma.<sup>27</sup> Patients with aspergillosis require a complete medical workup to discover any predisposing systemic conditions (ie, diabetes, transplantation surgery, malignancy, or acquired immunode-

iciency syndrome). However, unlike most fungal diseases, aspergillosis is often found without predisposing systemic factors. In such cases, local factors such as obstructive lesions of the nose and paranasal sinuses usually predispose patients to this opportunistic infection.<sup>5</sup> However, this could not be verified retrospectively in the present patient because of extensive tissue destruction. Treatment of antral aspergillosis is usually wide excision, adjunctive antifungal therapy, and supportive care. Intravenous amphotericin B is the drug of choice for invasive disease, and a daily dose of 0.5 to 0.8 mg/kg or up to double that dose given every other day for a minimum total dose of 2 g should be administered to adult patients for 6 to 8 weeks with close monitoring for possible side effects.

Detection of galactomannan antigen, an exoantigen of *Aspergillus*, has recently been shown to be a useful screening test for early diagnosis of invasive aspergillosis.<sup>28</sup> Galactomannan antigen positivity can be detected 5 to 8 days (average) before clinical signs develop in most patients. Detection of positive results particularly in 2 consecutive serum samples provides strong support for the diagnosis of invasive aspergillosis.<sup>28</sup>

Early diagnosis with the galactomannan antigen test, thorough surgical debridement, appropriate antifungal therapy, and control of any local or systemic predisposing factors are key in resolving the infection and lowering the rate of mortality.

## References

1. Neville BW: Fungal and protozoal diseases, *in* Neville BW, Damm DD, Allen CM, Bouquot JE (eds): Oral and Maxillofacial Pathology. Philadelphia, WB Saunders, 2009, p 232
2. Regezi JA: Mucormycosis and aspergillosis, *in* Regezi JA, Sciubba J, Pogrel MA (eds): Atlas of Oral and Maxillofacial Pathology. Philadelphia, WB Saunders, 2000, pp 12
3. Neville BW: Fungal and protozoal diseases, *in* Neville BW, Damm DD, Allen CM, Bouquot JE (eds): Oral and Maxillofacial Pathology. Philadelphia, WB Saunders, 2009, p 234
4. Karabulut AB, Kabakas F, Berkoz O, et al: Hard palate perforation due to invasive Aspergillosis in a patient with acute lymphoblastic leukemia. *Int J Pediatr Otolaryngol* 69:1395, 2005
5. Topazian RG, Waldron CA: Uncommon infections of the oral and maxillofacial regions, *in* Topazian RG, Goldberg MH (eds): Oral and Maxillofacial Infections. Philadelphia, WB Saunders, 1994, p 408
6. Napoli JA, Donegan JO: Aspergillosis and necrosis of maxilla: A case report. *J Oral Maxillofac Surg* 49:532, 1991
7. Pogrel MA, Miller CE: A case of maxillary necrosis. *J Oral Maxillofac Surg* 61:489, 2003
8. Neville BW: Salivary gland pathology, *in* Neville BW, Damm DD, Allen CM, Bouquot JE (eds): Oral and Maxillofacial Pathology. Philadelphia, WB Saunders, 2009, p 492
9. Neville BW: Salivary gland pathology, *in* Neville BW, Damm DD, Allen CM, Bouquot JE (eds): Oral and Maxillofacial Pathology. Philadelphia, WB Saunders, 2009, p 495
10. Neville BW: Hematologic disorders, *in* Neville BW, Damm DD, Allen CM, Bouquot JE (eds): Oral and Maxillofacial Pathology. Philadelphia, WB Saunders, 2009, p 602
11. Neville BW: Allergies and immunologic diseases, *in* Neville BW, Damm DD, Allen CM, Bouquot JE (eds): Oral and Maxillofacial Pathology. Philadelphia, WB Saunders, 2009, p 345
12. Neville BW: Salivary gland pathology, *in* Neville BW, Damm DD, Allen CM, Bouquot JE (eds): Oral and Maxillofacial Pathology. Philadelphia, WB Saunders, 2009, p 471
13. Neville BW: Bone pathology, *in* Neville BW, Damm DD, Allen CM, Bouquot JE (eds): Oral and Maxillofacial Pathology. Philadelphia, WB Saunders, 2009, p 669
14. Farrugia MC, Summerlin DJ, Krowiak E, Huntley T, Freeman S, Borrowdale R, et al: Osteonecrosis of the mandible or maxilla associated with the use of new generation bisphosphonates. *Laryngoscope* 116:115, 2006
15. Neville BW: Physical and chemical injuries, *in* Neville BW, Damm DD, Allen CM, Bouquot JE (eds): Oral and Maxillofacial Pathology. Philadelphia, WB Saunders, 2009, p 296
16. Little JW: Syphilis: An update. *Oral Surg Oral Med Oral Pathol Oral Radiol Endod* 100:3, 2005
17. Eng H-L, Lu S-Y, Yang C-H, et al: Oral tuberculosis. *Oral Surg Oral Med Oral Pathol Oral Radiol Endod* 81:415, 1996
18. Sakellariou PL: Periapical actinomycosis: Report of a case and review of the literature. *Endod Dent Traumatol* 12:151, 1996
19. Miller M, Haddad AJ: Cervicofacial actinomycosis. *Oral Surg Oral Med Oral Pathol Oral Radiol Endod* 85:498, 1998
20. Hall HD, Jacobs JS, O'Malley JP: Necrosis of maxilla in patient with herpes zoster: Report of a case. *Oral Surg Oral Med Oral Pathol* 37:657, 1974
21. Michael TS, Allen S, Stephen JC: Invasive aspergillosis of the maxilla in an immunocompromised patient. *Oral Surg Oral Med Oral Pathol* 70:425, 1990
22. Notani K, Satoh C, Hashimoto I, et al: Intracranial aspergillus infection from the paranasal sinus. *Oral Surg Oral Med Oral Pathol Oral Radiol Endod* 89:9, 2000
23. Tugsel Z, Sezer B, Akalin T: Facial swelling and palatal ulceration in a diabetic patient. *Oral Surg Oral Med Oral Pathol Oral Radiol Endod* 98:630, 2004
24. Jahndoefer RA, Ejercilo VS, Johns MM, et al: Aspergillosis of the nose and paranasal sinuses. *Am J Otol* 1:6, 1979
25. Khonkhunthian P, Reichart PA: Aspergillosis of the maxillary sinus as a complication of overfilling root canal material into the sinus: Report of two cases. *J Endod* 27:476, 2001
26. Beck-Mannagetta J, Necek D, Grasserbauer M: Solitary aspergillosis of maxillary sinus, a complication of dental treatment. *Lancet* 8361:1260, 1983
27. Vennwald I, Henker M, Seebacher C: Fungal colonization of the paranasal sinuses. *Mycoses* 42:33, 1999
28. Penack O, Rempf P, Graf B, et al: *Aspergillus* galactomannan testing in patients with long-term neutropenia: Implications for clinical management. *Ann Oncol* 19:984, 2007